Journal of Zoo and Wildlife Medicine 37(4): 571–573, 2006
Copyright 2006 by American Association of Zoo Veterinarians

CLINICAL CHALLENGE

Justin D. Brown, D.V.M., M. Kevin Keel D.V.M., Ph.D., Dipl. A.C.V.P., Michael J. Yabsley, Ph.D., Tyler Thigpen, and John C. Maerz, Ph.D.

Key words: *Plethodon metcalfi*, salamander, mites, dermatitis, trombiculidiasis, *Hannemania*.

HISTORY

Three free-living adult southern gray-cheeked salamanders (*Plethodon metcalfi*) were collected as part of a field research project. Two of the salamanders had orange to tan nodules on their skin, but they ate and behaved normally for the 2 days they were held in captivity. The salamanders with skin lesions were submitted to the Southeastern Cooperative Wildlife Disease Study (College of Veterinary Medicine, University of Georgia, Athens, Georgia 30602, USA) for diagnostic examination, where they were humanely euthanized and necropsies were performed. Both had multiple, 1.0–2.0-mm-diameter, tan to orange, nonulcerated nodules on the skin. One salamander had four nodules on the dorsal surface of the left rear foot, and the other had 15 nodules on the skin of the ventral half of its body. In some areas, the nodules appeared to coalesce. The salamander with four nodules was missing the second digit on the right rear foot. No other gross lesions were present.

Please examine the gross lesions in Figure 1 before continuing.

From the Southeastern Cooperative Wildlife Disease Study, Department of Population Health, College of Veterinary Medicine, University of Georgia, Athens, Georgia 30602, USA (Brown, Keel, Yabsley); and the Daniel B. Warnell School of Forestry and Natural Resources, University of Georgia, Athens, Georgia 30602, USA (Yabsley, Thigpen, Maerz). Correspondence should be directed to Dr. Justin D. Brown.



Figure 1. **A.** Multifocal nodules (arrowheads) on the skin of a southern gray-cheeked salamander. **B.** Magnified image of the nodules (arrowhead) on the right front limb.

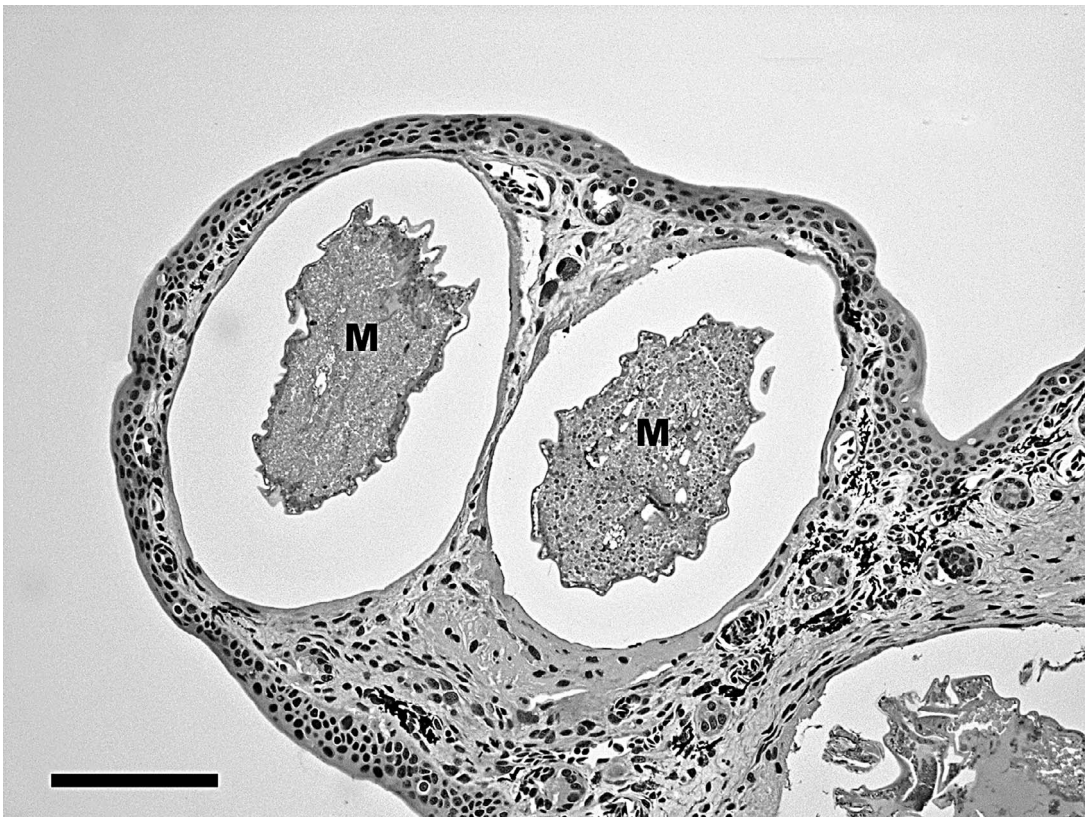

Figure 2. Skin; southern gray-cheeked salamander. A well-demarcated zone of macrophages, multinucleate giant cells, fibroblasts, fewer eosinophils, and fibrous connective tissue surrounds the mites (M). Hematoxylin and eosin. Bar = 200 μm.

DIAGNOSIS

Skin, moderate, chronic, multifocal, histiocytic dermatitis with intralesional trombiculid mites (*Hannemania* sp.).

DISCUSSION

Differentials for scattered nodules in the skin of a salamander include encysted larval nematodes or trematodes; encapsulated ectoparasites; neoplasia; and inflammation associated with viral, bacterial, or fungal infection. In cases of trombiculidiasis, mites can be detected in the nodules by close inspection with a hand lens or by histopathologic examination (Fig. 2). Speciation, however, requires examination of the whole mite after it has been dissected free of the nodule. Many larval mites can only be identified to genus because the free-living adults are often required for specific identification. Larval trombiculid mites can be differentiated from other common ectoparasites by 1) morphology of mouthparts (gnathostoma), 2) presence of three rather than four pairs of legs as found on adult mites, or nymphal or adult ticks, and 3) presence of numerous ventral setae. The larval mites were identified to the genus *Hannemania* on the basis of the following characteristics: 1) six, rather than seven, segments on each leg; 2) small projection on the anteriomedian region of the scutum; 3) paired submedian anterior scutal setae; and 4) presence of teeth on greatly modified and expanded cheliceral blades.[8] *Hannemania* spp. are only parasitic on amphibians. The digit missing from one of the salamanders could also be a result of the infestation because musculoskeletal lesions (including loss of digits) have been observed on the feet and toes of other salamanders infested with trombiculid mites.[2]

Infestation with the larval stage of trombiculid mites (chiggers) has been reported in a variety of North American reptile and amphibian species.[5,7] The mites were predominately of the genus *Hannemania*. In the eastern and central states, *Hannemania dunni* was the most frequently reported species. Amphibian chiggers penetrate through the skin of the host and remain embedded in the dermis

for months,[3] The inflammation associated with these intradermal mites is usually mild and consists of macrophages and fibrous connective tissue.[5] Susceptibility of an amphibian to infestation with *Hannemania* mites depends on multiple factors, including the species and gender of the amphibian host, the habitat, and the geographic region. Mites in the genus *Hannemania* are not host species specific, but infestations are reported more frequently in certain amphibian groups, including woodland (lungless) salamanders (*Plethodon* spp.), true frogs (*Rana* spp.), toads (*Bufo* spp.), and treefrogs (*Hyla* spp.).[3] Variability in the prevalence of *Hannemania* infestation is significant between sympatric amphibian species.[4] In addition, the site and distribution of infestation appears to differ between host species.[1] *Hannemania* were found more frequently on terrestroaquatic species of amphibians than aquatic species within the same geographic area, indicating that the habitat of the host might be a predisposing factor to mite infestation.[6] *Hannemania* spp. are present throughout the Western Hemisphere.[5] In North America, they have been reported on amphibians in several states in the central and southeastern United States.[7] However, within this region, the prevalence of mite infestation appears to be largely variable. Male plethodontid salamanders were shown to be infested more frequently than females, which might be a result of the wider home range of males and the increased likelihood of contact with the parasite.[1]

Trombiculidiasis is a disease of free-living amphibians and infestation is rare in captive bred populations.[7] The pathology and potential for disease with *Hannemania* infestation is not completely known. Mortality associated with infestation has not been reported in free-living amphibians.[3] However, three of six wild-caught, captive canyon tree frogs (*Hyla aernicolor*) infested with *Hannemania* mites died while in captivity, in spite of ivermectin treatment.[7] The remaining three frogs fully recovered after manual extraction of the mites and a similar treatment regime with ivermectin. The cause of death was not definitively determined. Because no other infectious agents were identified, it is possible that the mortality was directly or indirectly caused by the mites. Possible mechanisms for amphibian mortality associated with mite infestation include 1) disruption of normal physiologic mechanisms such as transdermal respiration; 2) presdisposition of the host to secondary bacterial, viral, or fungal infections; 3) musculoskeletal lesions with motor dysfunction that could predispose to predation; and 4) impaired sensory perception from occlusion of the nasolabial groove. Anthony et al.[1] noted that many *Plethodon ouachitae* and *Plethodon caddoensis* had larval mites embedded in the snout, resulting in occlusion of the nasolabial groove. The nasolabial groove plays an important role in transporting substances to the vomernasal organ, and damage to this structure could result in impaired ability to forage or find a mate.[1]

Although the implications of trombiculidiasis in free-living amphibians (individual animals or the population) are not completely known, mite infestations are fairly common in some areas of the southeast and central United States. Biologists and veterinarians working with free-living and captive amphibians should be able to recognize lesions that are consistent with mite infestation and be able to apply the appropriate measures to confirm the diagnosis.

Acknowledgment: We thank J. P. Bond for technical expertise.

LITERATURE CITED

1. Anthony, C. D., J. R. Mendelson, and R. R. Simons. 1994. Differential parasitism by sex on plethodontid salamanders and histological evidence for structural damage to the nasolabial groove. Am. Midl. Nat. 132: 302–307.

2. Conant, R., and J. T. Collins. 1991. A Field Guide to Reptiles and Amphibians of Eastern and Central North America. Houghton Mifflin Co., Boston, Massachusetts. P. 450.

3. Converse, K. A., and D. E. Green. 2005. Diseases of Salamanders. *In:* Majumdar, S. K., J. E. Huffman, F. J. Brenner, and A. I. Pannah (eds.). Wildlife Diseases: Landscape Epidemiology, Spatial Distribution, and Utilization of Remote Sensing Technology. The Pennsylvania Academy of Sciences, Easton, Pennsylvania. Pp. 126–130.

4. Duncan, R., and R. Highton. 1979. Genetic relationships of the eastern large *Plethodon* of the Ouachita Mountains. Copeia. 1979: 95–110.

5. Green, D. E. 2001. Pathology of Amphibia. *In:* Wright, K. M., and B. R. Whitaker (eds.). Amphibian Medicine and Captive Husbandry. Krieger Publishing Co., Malabar, Florida. Pp. 401–485.

6. Murphy, T. D. 1965. High incidence of two parasitic infestations and two morphological abnormalities in a population of the frog, *Rana palustris* Le Conte. Am. Midl. Nat. 74: 233–239.

7. Sladky, K. K., T. M. Norton, and M. R. Loomis. 2000. Trombiculid mites (*Hannemania* sp.) in canyon tree frogs (*Hyla arenicolor*). J. Zoo Wildl. Med. 31: 570–575.

8. Wharton, G. W., D. W. Jenkins, J. M. Brennan, H. S. Fuller, G. M. Kohls, and C. B. Philip. 1951. The terminology and classification of trombiculid mites (Acarina: Trombiculidae). J. Parasitol. 37: 13–31.

Received for publication 11 January 2006